

Prolotherapy For Knee Pain

A reasonable and conservative approach to knee tendonitis/tendonosis, sprain-strains, instability, diagnosis of meniscal tear, patellofemoral pain syndrome including chondromalacia patellae, degenerative joint disease, and osteoarthritis pain



By Donna Alderman, DO

Prolotherapy is a method of injection treatment designed to stimulate healing.¹ Many musculoskeletal injuries and pain syndromes lend themselves to prolotherapy treatment including low back and neck pain, chronic sprains and/or strains, whiplash injuries,

tennis and golfer's elbow, knee, ankle, shoulder or other joint pain, chronic tendonitis/ tendonosis, and musculoskeletal pain related to osteoarthritis. Prolotherapy works by raising growth factor levels or effectiveness to promote tissue repair or growth.² It can be used years after the ini-

tial pain or problem began, as long as the patient is healthy.

This month's article focuses on the use of prolotherapy for knee pain and injuries, including ligament and meniscal injuries, tendonitis and tendonosis, patellofemoral syndrome, and osteoarthritis pain including degenerative joint disease.

Prolotherapy Mechanism of Action Review

Prolotherapy works by causing a temporary, low grade inflammation at the site of ligament or tendon weakness (fibro-osseous junction), "tricking" the body into initiating a new healing cascade. Inflammation activates fibroblasts to the area, which synthesize precursors to mature collagen, reinforcing connective tissue.² This inflammatory stimulus raises the level of growth factors to resume or initiate a new connective tissue repair sequence to complete one which had prematurely aborted or never started.² Prolotherapy is also known as "regenerative injection therapy (RIT)," "non-surgical tendon, ligament, and joint reconstruction" or "growth factor stimulation injection therapy."

Ligament Injuries Lead to Degenerative Arthritis

Osteoarthritis almost always begins as ligament weakness.³ Unresolved ligament sprains (overstretching) results in ligament relaxation and weakness. Relaxation of the ligament results in joint instability and a change in joint biomechanics which eventually results in osteoarthritis of that joint as bones glide over each other unevenly. The observation that bones remodel and grow in response to their mechanical environment is best explained in Wolff's Law which states:

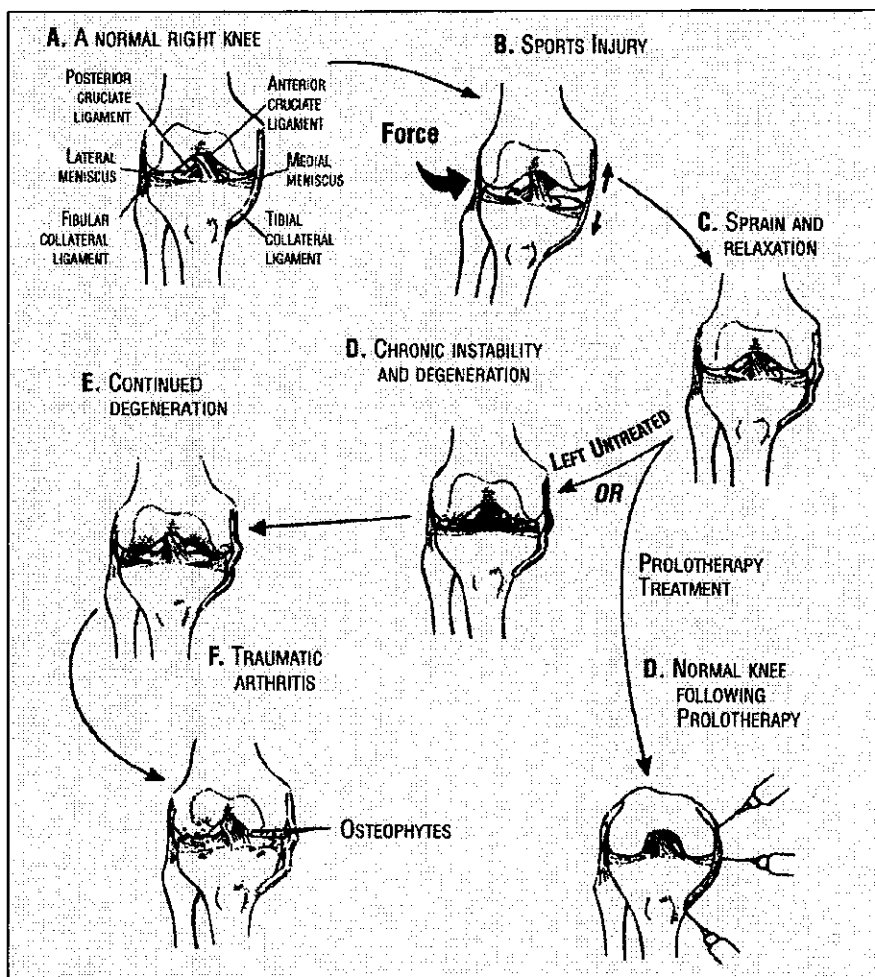


FIGURE 1. How soft tissue injury leads to degenerative arthritis. From Hauser, "Prolotherapy: An Alternative to Knee Surgery," Beulah Land Press, Oak Park, IL, 2004. Used with permission.

"Bones respond to stress by making new bone."⁴ Tendon injuries, if unresolved, over a long period of time also have an influence on joint biomechanics and can contribute to the development of osteoarthritis.

This has been well demonstrated in the medical literature. One study of female soccer players who had sustained knee ligament injuries showed a very high percentage with knee osteoarthritis 12 years later.⁵ Another study, published in *Sports Medicine*, observed the increased incidence of osteoarthritis with individuals who engaged in certain sports. These included wrestlers, boxers, baseball pitchers, football players, ballet dancers, soccer players, weightlifters, cricket players, and gymnasts.⁶ Postgraduate Medicine reports in its investigation of the causes of human arthritis:

"There is no question that trauma and mechanical stress on the joint lead to the development of osteoarthritis."⁷

Even in veterinary medicine, it is well-established that ligament sprains favor the development of osteoarthritis in animals.⁸

If ligament and tendon injuries are stimulated to heal, biomechanics can be restored and the downward progression of degenerative changes can be prevented or stopped. Prolotherapy can, therefore, be seen as a method to prevent or stop the arthritic process because it strengthens the joint and thus ends the need for the knee or other treated joint, to grow bone or form bone spurs⁹ (see Figure 1).

Prolotherapy for Patients with Degenerative Arthritis

Prolotherapy has been used successfully even after the diagnosis of osteoarthritis and degenerative joint disease. This may be because of its ability to strengthen the existing intact, but weakened, ligamentous and tendinous structures. There is also some clinical evidence that prolotherapy may help to regenerate cartilage. Reeves and Hassanein in Kansas City investigated prolotherapy in degenerative osteoarthritis with and without ACL laxity. In their double blind, placebo-controlled study, enrolled patients had either grade 2, or more, joint narrowing or grade 2, or more, osteophytic change. In addition to subjective indexes such as visual analogue scale for pain, swelling, and frequency of leg buckling, objective goniometric flexion measurements as well as radiographic measures of joint narrowing

and osteophytosis were taken before and after prolotherapy. Arthrometric measurements of ACL laxity were also done. The study concluded that prolotherapy treatment resulted in clinically and statistically significant improvements in knee osteoarthritis. Preliminary blinded radiographic readings (1-year) demonstrated improvement in several measures of osteoarthritic severity. ACL laxity, when present, also improved.¹⁰

Cartilage Regeneration

Clinical evidence exists that prolotherapy can help to stimulate cartilage regeneration, although no specific controlled studies have yet been done to confirm this. Laboratory studies have demonstrated that cartilage cells respond to injury (inflammation) by changing into chondroblasts, cells capable of cell proliferation, growth, and healing.¹¹ Therefore, it would be logical that in vivo use might stimulate a similar phenomenon. One case report by Dr. Ross Hauser in Oak Park, Illinois, showed clinical evidence of such a change. X-rays were taken of a patient with severe knee osteoarthritis one year apart, before and after prolotherapy treatments (see Figure 2). The patient was a 62 year old female who, when first seen, was unable to ambulate without a cane. After 12 prolotherapy sessions this patient was pain free with full mobility. Clearly, more clinical trials need to be done, and this would be a good future area of investigation.

MRIs Can Be Misleading

When deciding what patients are candidates for prolotherapy, do not be misled

by the MRI or use the MRI for diagnosis alone. MRI's may show abnormalities not related to the patient's current pain complaint and so should always be correlated to the individual patient. Many studies have documented the fact that abnormal MRI findings exist in large groups of pain-free individuals.¹²⁻¹⁸ The finding of asymptomatic changes in knee joints during surgery is also not uncommon.^{19,20} One study looked at the value of MRI's in the treatment of knee injuries and concluded "Overall, magnetic resonance imaging diagnoses added little guidance to patient management and at times provided spurious [false] information." So do not use an MRI alone to determine a treatment course. The MRI should be used in combination with a history of the complaint, precipitating factors or trauma, and a physical exam.

Meniscal Injury

The meniscus is a C-shaped region of fibrocartilage between the femur and the tibia which provides shock absorption. There is a medial and a lateral meniscus, with the medial being the more commonly injured (see Figure 3). Meniscal tears are a common diagnosis, in part because MRI's clearly show these tears. However, as noted above, MRIs can be misleading, and this is especially true with the meniscus. A knee MRI study addressed this issue. The authors looked for meniscal abnormalities in asymptomatic, pain-free individuals aged in their 20s to 80s and found Grade 1, 2 and 3 changes present in essentially all decades, with an increase in prevalence with increasing age. 62% of individuals as

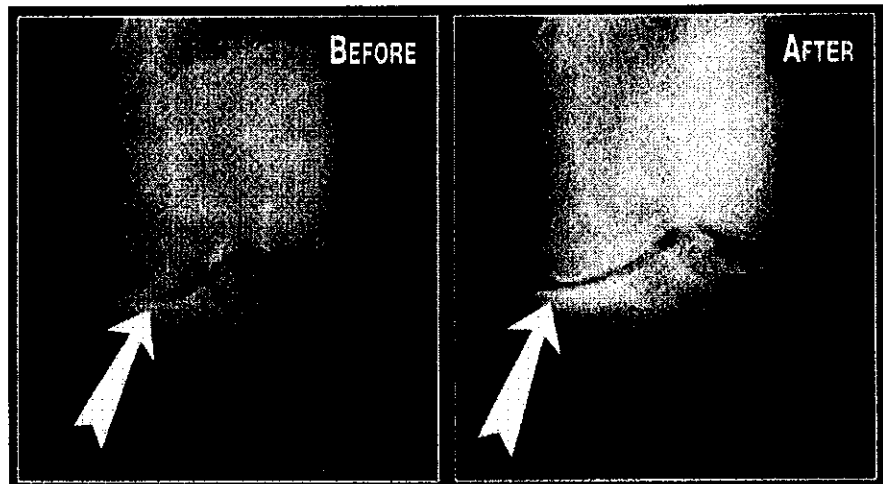


FIGURE 2. Xray before and after Prolotherapy. From Hauser, *Prolotherapy: An Alternative to Knee Surgery*, Beulah Land Press, Oak Park, IL, 2004. Used with permission.

Case Reports

Case #1

51 year-old cameraman complaining of left knee pain for 6 months which began after a two foot fall from an unstable riser at work. Two weeks after this injury, the patient was running, as was his routine, and began to notice discomfort in his left knee. Discontinuing running helped but, while at his daughter's soccer game, he ran after a ball and a week later began to have the same pain recur in his knee and has persisted. He feels the pain in the medial aspect of his knee when going up and down stairs, worse going up, and also when walking. NSAIDs have not helped. He has been told he has a torn meniscus and arthritis causing his pain.

Medical History: No major surgeries or medical issues.

Review of Systems: No complaints other than seasonal allergies.

Medications: Claritin

Physical Exam: Left knee slightly swollen as compared to left, but without erythema or deformity. Flexion to 110 degrees, with restricted extension secondary to apparent Bakers cyst. Mild crepitus present. +1/2 drawer sign with lateral to medial motion present. Negative McMurray's. Tenderness present at the medial collateral ligament and pes anserius tendons.

MRI: 1. Mild tricompartmental osteoarthritis with cartilage loss most severe in the lateral facet and trochlea; 2. Complex grade III signal in the posterior horn of the medial meniscus and body compatible with tearing; 3. Mild anterior cruciate ligament sprain as well as a grade I medial collateral ligament sprain. Meniscocapsular separation cannot be excluded as the edema is most intense adjacent to the meniscus; 4. Small joint effusion and small lobulated popliteal cyst.

Prolotherapy Treatment: After 5 prolotherapy treatments one month apart, the patient reported 90% improvement. At the patient's followup visit and treatment 3 months later, he reported continued improvement, now 95%, and reports no pain with return to regular exercise. At one year follow up, the patient reports continued stability and activity.

Case #2

63 year-old male, public relations executive, with 20 year history of left knee pain on and off, status post 2 knee arthroscopic surgeries which gave him only short-term relief. Over the past few years, he states the pain has worsened and recently exacerbated with a lifting injury. He has taken NSAIDs such as Bextra which temporarily help, and followed the RICE protocol (rest, ice, compression, elevation), but the pain has continued. He has stiffness and difficulty getting up from seated to standing position, and trouble going down stairs. He has been told he has cartilage degeneration and needs a knee replacement.

Medical History and Review of Symptoms: Tonsils out as a child and measles at age 30. No health issues except elevated blood pressure, on medication.

Medications: Aspirin, Cozaar, Effexor, Bextra prn.

Examination: Valgus deformity, left greater than right.

Flexion is restricted at 90 degrees of flexion with restricted extension of 10 degrees from flat. There is mild swelling but no erythema. Tenderness to palpation at the medial collateral ligament and pes anserius tendon. +1/2 drawer sign and negative McMurray.

Prolotherapy Treatment: After 10 prolotherapy treatments one month apart, the patient felt he was 85% improved and was no longer considering a knee replacement. He reported far less pain under load and resting, better flexibility, walking down stairs easily, and no stiffness when getting up from sitting or after driving. At 2-1/2 year follow-up, he had continued stability with range of motion only mildly restricted in extension and with full range of motion in flexion.

Case #3

14 year-old male with anterior knee pain for one year after being active in several sports for many years, including basketball, football, soccer and baseball. No prior known trauma. He states he was diagnosed with Osgood-Schlatter disease and was told there was nothing he could do about it. The patient wakes up in the morning with the pain and it lasts throughout the day and has prevented him from participating in his usual sports. Subsequently, he dropped out of all his athletic activities and is not currently active in any sport yet still experiences daily pain.

Medical History and Review of Systems: Negative

Medications: None

Examination: Enlargement of the tibial tuberosity with tenderness to palpation at the patellar tendon insertion on the tuberosity bilaterally. Rest of exam within normal limits.

Prolotherapy Treatment: After one treatment to the right knee and three treatments to the left knee at 3 to 4 week intervals, patient states he is 95-100% better in both knees, and back to full sports activity. He reports he can now "do anything." Followup at 1 and 2 years showed stable improvement with continued full return to all sports.

Case #4

32 year-old female, former Olympic Taekwondo competitor, with history of right knee pain for three years, status post ACL reconstruction (patella technique) with partial medial meniscectomy. The patient's pain returned 1 year later and she underwent arthroscopic debriding which confirmed damage to her articular cartilage. This provided only temporary relief. She has done rehab exercise on her own but despite this, over the last year, medial knee pain has returned and is now persistent and fairly constant. The pain is aggravated by walking and activity.

Medical History and Review of Systems: Healthy, no health issues or complaints.

Medications: None

Exam: Right knee: patellar tracking deficit and crepitus. +2 drawer sign. Range of motion within normal limits. Negative McMurray. Tender to palpation at MCL, patellar tendon and pes anserius tendon insertion.

Prolotherapy Treatment: The patient was given six treatments on her right knee, approximately every 4 weeks. She felt immediate reduction in her pain starting with the first

treatment. She was able to return to teaching fitness classes, did a 100 mile cycling trip, and had continued reduction in pain with each treatment. At follow up visit one year later, the patient reports an overall 80% improvement, with exam demonstrating negative drawer sign and reduction in patellar crepitus.

Case #5

57 year-old male complaining of 3 year history of right knee pain with onset while jogging. He used to run an average of 5 km per day. At the time he was told to discontinue jogging but was subsequently never able to return to that sport. He had an MRI recently which showed a medial meniscal tear. He has continued to have pain, which has worsened over the last 3 months with increased instability and pain, and has also noticed he has begun to limp, especially when going down stairs, with sudden movements, or while hiking.

Medical History: Hernia operation age 5, otherwise no surgeries and no major illnesses.

Medications: None.

Examination: Gait mildly antalgic. Right knee exam shows normal 110 degrees of flexion, extension normal, with mild patellar crepitus and some osteophytic overgrowth, right v. left. +1/2 drawer sign with some lateral to medial motion. Mildly tender to palpation at MCL and pes anserius tendon on the right.

MRI: Grade III tear of posterior horn of the medial meniscus. Signal abnormality involving the articulating surface of the lateral femoral condyle. This could represent early stage of chondromalacia, although the possibility of a small osteochondral defect with intact overlying articulating cartilage cannot be entirely excluded.

Prolotherapy Treatment: After 6 prolotherapy treatments approximately every 4 weeks, patient reports he is "99.9% recovered." He indicates a full return to activity, increased stability, and pain resolution.

young as their 20s had abnormal medial meniscal scans while 90% of scans were abnormal for pain-free individuals in their 70s.²¹

Another interesting note is that the medial meniscus firmly adheres to the deep surface of the medial collateral ligament (MCL), an important stabilizing ligament.²² Therefore injury to the medial meniscus will very often also result in injury and sprain to the MCL. The cause of the knee pain may be the MCL sprain, but MCL sprains are usually not addressed, especially if the MRI shows a meniscal tear. This could explain pain persisting after meniscal surgery. Clearly, the presence of meniscal tears on MRI needs to be correlated to an individual's pain complaint. Pain may not be related to the abnormal findings on an MRI, but rather may be due to ligament or tendon injury or sprain/strain. In fact, individuals with abnormal MRI's showing meniscal tears have successfully been treated with prolotherapy. It is unclear whether prolotherapy has any direct effect on meniscal tissue, and this has not been specifically studied. However, even when patients have these meniscal abnormalities on MRI, they often improve after prolotherapy treatment.

Tendonitis vs. Tendonosis

Tendonitis is defined as "an inflammatory condition of a tendon, usually resulting from strain."²³ If the condition has gone on longer than 6 weeks, it is sometimes called chronic tendonitis. However, biopsies of "chronic tendonitis" tissue have shown lack of inflammatory cells and repair, but rather collagen degeneration occurring.²⁴⁻²⁶ For this reason, in recent years the word "tendonosis" ("osis" meaning diseased or abnormal condition) is being used in the medical literature to describe what has previously been known as chronic tendonitis, and which some authors believe may be a more accurate diagnosis. In this type of tendonopathy, inflammation is no longer occurring and collagen breakdown is the primary problem. Traditional treatments include NSAID's and corticosteroids yet studies provide little evidence that these treatments are helpful.²⁷ Therefore treatment should target the stimulation of collagen production rather than the elimination of inflamma-

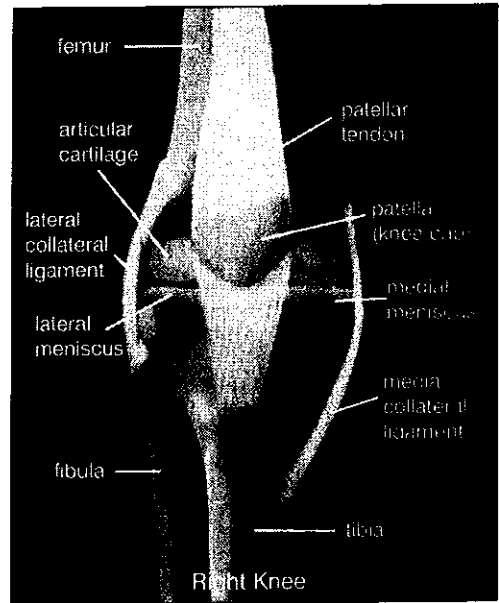


FIGURE 3. Anatomy of the knee joint.

tion since the latter may not even be present.²⁸ Prolotherapy is a more reasonable treatment option since the focus is to stimulate the proliferation of fibroblasts which then stimulate collagen repair and proliferation. With prolotherapy, the tendonosis is turned into a tendonitis (on purpose) in order to reactivate the repair process and create a stronger tendon.²⁹

Osgood-Schlatter Disease

Osgood-Schlatter disease is one of the most common sports-limiting orthopedic conditions in adolescent athletes.³⁰ It is thought to be caused by small, usually unnoticed, injuries to the patellar tendon as it connects to the articular cartilage on the tibial tuberosity, caused by repeated overuse before growth of the area is complete. This disorder is seen most often in active, athletic adolescents, usually between ages 10 and 15, and is common in adolescents who play soccer, basketball, volleyball, and gymnastics. It is now believed to be a degenerative condition "osis," rather than an inflammatory "itis," and explains why arthritis anti-inflammatory medications offer no long-term benefit.³¹ Prolotherapy has effectively been used to treat this condition, and offers new hope to this previously difficult to treat condition. Research is currently ongoing and volunteers are being recruited for a clinical trial. More information regarding these trials and patient eligibility are available at the website www.dr-reevesonline.com.

Anterior Cruciate Ligament Injury

The Anterior Cruciate Ligament (ACL) is an important ligament for anterior-posterior stability of the knee. An estimated 200,000 ACL-related injuries occur annually in the United States,³² with the highest incidence in those who participate in pivoting sports such as soccer, volleyball, and basketball. Thirty percent of these injuries are a result of direct contact with an object or another player, while 70% do not involve direct contact and the basic injury mechanism may be elusive.³³ Risk factors

knee.³⁹ The patient experiences a crack and feels a sudden pain at the inner aspect of the knee. Most of the pain disappears relatively quickly and, at first, the knee is not swollen. However, increasing pain and swelling starts after a few hours. By the next day, the patient can hardly stand. This improves over a period of time and, after 2 to 3 months, should be completely resolved. If any residual pain exists, the ligament has likely been permanently lengthened, resulting in an unstable knee.⁴⁰ As discussed above, leaving an

overuse injury in sports such as volleyball, basketball, cycling, and high-jump.⁴⁵ Three possible sites exist: the upper border (suprapatellar), the apex, which is the classical "jumper's knee" (infrapatellar), and at either side of the patella (tendonitis of the quadriceps expansion).⁴⁴ Patient history typically includes localized pain at the front of the knee during or after exertion. In severe cases, there is pain at rest with less severe cases exhibiting only minor pain after exercise. The patient also states that walking upstairs or getting up from a chair is painful.⁴⁵ Physical exam is usually normal. MRI diagnosis is not very helpful in this diagnosis and adds little guidance to patient management.^{46,47} Patellar tendonitis can progress to tendonosis and make its management more recalcitrant. Again, prolotherapy can be effective in treating this tendonitis/tendonosis.

"If the ACL is completely ruptured, surgery is needed. However, for partial ACL injury, prolotherapy is a reasonable treatment option and should be considered prior to surgery."

include activities involving deceleration, pivoting, awkward landings, shoe-surface interactions, and other mechanical environmental factors.³⁴ While ACL injuries are a very common knee injury, they often do not heal well. This is because the blood supply is from within the ligament itself, not from around it, and when the ligament is torn the blood supply is commonly disrupted during the injury.³⁵ If the ACL is completely ruptured, surgery is needed. However, for partial ACL injury, prolotherapy is a reasonable treatment option and should be considered prior to surgery. As discussed above, Reeves et al. demonstrated the effectiveness of prolotherapy for ACL laxity.³⁶ MRI studies have not been shown to be as accurate as one might think in the differentiation of complete and partial ACL tears,³⁷ therefore correlation between history, physical exam, and MRI is important in determining who is a candidate for prolotherapy.

Medial Collateral Sprain

The medial collateral ligament (MCL) (also called tibial collateral ligament) is an important stabilizing ligament of the knee. The MCL sprain is a common injury, especially in sports but this injury can also occur in the non-athlete. The classical mechanism of a medial collateral ligament is a force hitting the lateral aspect of a partly flexed and externally rotated knee³⁸—such as would occur with a soccer or football player who receives a kick or blow at the outer side of a weight-bearing

unstable ligament will result in a change in biomechanics and development of osteoarthritis. Prolotherapy can be used in this situation to repair the overstretched ligament and stimulate healing so that stability is restored.

Coronary Ligament Sprain

These small, but very important, ligaments hold the outside edge of the meniscus to the tibial plateau. They are very commonly injured but mostly go undiagnosed because the localization of the pain and nature of the onset resemble a meniscus lesion or a sprain of the medial collateral ligament.⁴¹ These injuries can be effectively treated with prolotherapy.

Pes Anserinus Tendonitis

The pes anserinus group of tendons attach at the medial knee and are a very common area of injury and source of pain in all age groups. The pes anserinus is the combined tendon insertions of three muscles (sartorius, gracilis, and semitendinosus) at the anteromedial aspect of the proximal tibia. This tendonitis is sometimes misdiagnosed as pes anserinus bursitis, however bursitis in this location is rare.⁴² Pes anserinus tendonitis is very common in older individuals, and may remain after knee replacement surgery. Pes anserinus tendonitis is easily treated with prolotherapy.

Patellar Tendonopathy

Tendonitis around the patella is a typical

Patellofemoral Pain Syndrome (Pfps)

Patellofemoral pain is the most common cause of anterior knee pain,⁴⁸ usually presenting with vague symptoms of pain "in," "under," or "behind" the patella or in the peri-patellar area. Symptoms are exacerbated by activities such as running, descending stairs, and squatting, as well as prolonged sitting with the knee in a flexed position ("theatre sign"). Twenty-five percent of the population, at some stage in their lives, suffer from this condition.⁴⁹ Despite this, there is little agreement on the terminology, etiology, or treatment. The term "chondromalacia patellae" is sometimes used, but is now reserved for a small subset of anterior knee pain with documented softening of the patellar articular cartilage.⁵⁰ There is little evidence to support the use of knee braces or NSAIDs⁵¹ in PFPS. This condition has been successfully treated with prolotherapy.

Typical Treatment Course

The average number of prolotherapy treatments needed is 4 to 6, with some patients needing more and some patients less. Individuals with more severe degenerative changes may require more treatments while teenagers often require less. Patients who have been on anti-inflammatories prior to starting treatment may require additional treatments before improvement is noted. If no improvement whatsoever is noted by the patient after 3 to 4 treatments, there should be a re-eval-

uation for any interfering factors such as poor sleep, diet, continued aggravating activities, illness, or use of medications that may prevent healing. If indicated, the patient should be considered for referral for complimentary modalities, radiological studies, or surgical consult.

Contraindications

Active infection, cancer, non-reduced dislocations, or known allergy to any prolotherapy ingredients are contraindications to treatment, as is any known underlying illness which would interfere with healing. Acute gout or rheumatoid arthritis in the knee joint are also contraindications. Relative contraindications include current and long term use of high doses of narcotics as these medications can lower the immune response. Current use of systemic corticosteroids or NSAIDs are also relative contraindications as these are counter-productive to the inflammatory healing process.

Conclusion

Prolotherapy is a reasonable and conservative approach to knee tendonitis/tendonosis, knee sprain-strains, knee instability, diagnosis of meniscal tear, patellofemoral pain syndrome including chondromalacia patellae, as well as degenerative joint disease and osteoarthritis pain. Since prolotherapy is a treatment modality that provides a long term solution rather than just palliation, it should be considered in appropriate patients prior to long term narcotic therapy or surgical intervention. ■

Donna Alderman, DO is a graduate of Western University of Health Sciences, College of Osteopathic Medicine of the Pacific, in Pomona, California, with undergraduate degree from Cornell University in Ithaca, NY. She has extensive training in Prolotherapy and has been using Prolotherapy in her practice for ten years. Dr. Alderman is the Medical Director of Hemwall Family Medical Centers in California and can be reached through her website www.prolotherapy.com.

References

1. Hackett GS, Hemwall GA, and Montgomery GA. *Ligament and Tendon Relaxation Treated by Prolotherapy*. Fifth Edition. (1956 First Edition Charles C. Thomas, Publisher). Gustav A. Hemwall, Publisher. Institute in Basic Life Principles. Oak Brook, IL. 1991.
2. Reeves KD. Prolotherapy. Basic Science, Clinical Studies, and Technique. In Lennard TA (Ed) *Pain Procedures in Clinical Practice 2nd Ed.* Hanley and Belfus. Philadelphia. 2000. 172-190.

3. Hauser R. *Prolotherapy: An Alternative to Knee Surgery*. Beulah Land Press. Oak Park, IL. 2004. p 83.
4. Cervoni TD et al. Recognizing upper-extremity stress lesions. *The Physician and Sportsmedicine*. August 1997. (25):8.
5. Lohmander LS, Osterberg A, Englund M, and Roos H. High prevalence of knee osteoarthritis, pain and functional limitations in female soccer players twelve years after anterior cruciate ligament injury. *Arthritis & Rheumatism*. October 2004. 50(10):3142-3152.
6. Panush R. Recreational activities and degenerative joint disease. *Sports Medicine*. January 1994. 17:1-5.
7. Morehead K and Sack K. Osteoarthritis: What therapies for this disease of many causes? *Postgraduate Medicine*. November 2003. pp 12-17.
8. Farrow CS and Newton CD. "Ligamentous Injury (Sprain)" in *Textbook of Small Animal Orthopaedics*. International Veterinary Information Service. Ithaca, NY. 1985.
9. Hauser R. *Prolotherapy: An Alternative to Knee Surgery*. Beulah Land Press. Oak Park, IL. 2004. p 62.
10. Reeves KD and Hassanein K. Randomized prospective double-blind placebo-controlled study of dextrose prolotherapy for knee osteoarthritis with or without ACL laxity. *Alternative Therapies*. March 2000. 6(2):68-80.
11. Mankin H. The response of articular cartilage to mechanical injury. *Journal of Bone and Joint Surgery*. 1982. 64A:460.
12. Ombregt L, Bisschop P, and ter Veer HJ. *A System of Orthopaedic Medicine*, 2nd Edition. Churchill Livingstone. 2003. p 59.
13. MacRae DL. Asymptomatic intervertebral disc protrusion. *Acta Radiologica*. 1956. pp 46-49.
14. Hittselberger WE and Whitten RM. Abnormal myelograms in asymptomatic patients. *Journal of Neurosurgery*. 1968. 28:204.
15. Wiesel SW et al. A study of computer-assisted tomography: 1. The incidence of positive CAT scans in an asymptomatic group of patients. *Spine*. 1984. 9: 549-551.
16. Powell MC et al. Prevalence of lumbar disc degeneration observed by magnetic resonance in symptomless woman. *Lancet*. 1986; 13:1366-1367.
17. Boden SD et al. Abnormal magnetic resonance scans of the lumbar spine in asymptomatic subjects. *Journal of Bone and Joint Surgery* 1990. 72A:503-408.
18. Kaplan PA. MR imaging of the normal shoulder: variants and pitfalls. *Radiology*. 1992. 184:519-524.
19. Jerosch J, Castro WH, and Assheuer J. Age related magnetic resonance imaging morphology of the menisci in asymptomatic individuals. *Archives of Orthopedic Trauma Surgery*. 1996. 115(3-4); 199-202.
20. LaPrade RF et al. The prevalence of abnormal magnetic resonance imaging findings in asymptomatic knees. With correlation of magnetic resonance imaging to arthroscopic findings in symptomatic knees. *American Journal of Sports Medicine*. 1994. 22(6):739-745.
21. Kormick J, Trefelner E, McCarthy S et al. Meniscal abnormalities in the asymptomatic population at MR Imaging. *Radiology*. 1990. 177:463-465.
22. Moore K and Dalley A. *Clinically Oriented Anatomy, Fifth Edition*. Lippincott Williams & Wilkins. 2006. p 688.
23. *Mosby's Medical Dictionary*, Elsevier Saunders. 2006.
24. Astrom M and Rausing A. Chronic Achilles tendinopathy: a survey of surgical and histopathologic findings. *Clin Orthop*. July 1995. 316:151-164.
25. Khan KM, Bonar F, Desmond PM et al. Patellar tendinosis (jumper's knee); findings at histopathologic examination, US and MR imaging. Victorian Institute of Sport Tendon Study Group. *Radiology*. 1996. 200(3):821-827.
26. Khan KM, Cook JL, Bonar F et al. Histopathology of common teninopathies: update and implications for clinical managements. *Sports Medicine*. 1999. 27(6):393-408.
27. Almekinders LC and Temple JD. Etiology, diagnosis and treatment of tendonosis: an analysis of the literature. *Medicine & Science in Sports and Exercise*. 1998. 30(8).
28. Khan KM, Cook JL, Taunton JE, and Bonar F. Overuse Tendonosis, Not Tendonitis. *The Physician and Sportsmedicine*. May 2000. 28(5).
29. Hauser R. *Prolotherapy: An Alternative to Knee Surgery*. Beulah Land Press. Oak Park, IL. 2004. p 92.
30. Ross MD, Villard D. Disability of college-aged men with a history of Osgood-Schlatter disease. *J. Strength Cond. Res*. 2003. 17(4):659-663, cited in Reeves KD et al. Study seeks treatment to keep athletes in the game. *Biomechanics*. April 15, 2006.
31. Kader D, Saxena A, Movin T et al. Achilles tendinopathy: some aspects of basic science and clinical management. *British Journal of Sports Medicine*. 2002. 36(4):239-249, cited in Reeves, KD et al. Study seeks treatment to keep athletes in the game, *Biomechanics*. April 15, 2006.
32. www.emedicine.com/sports/TOPI9.HTM. Last visited 7/9/07.
33. Griffin LY, Agel J, Albohm MJ et al. Noncontact Anterior Cruciate Ligament Injuries: Risk Factors and Prevention Strategies. *Journal of the American Academy of Orthopaedic Surgeons*. May/June 2000. 8(3):141-150.
34. *Ibid*.
35. Rowley D. *The Musculoskeletal System*. Chapman & Hall Medical. 1997. New York, NY. p 73, cited in Hauser R. *Prolo Your Sports Injuries Away*. Beulah Land Press, Oak Park, IL. 2001. p 281.
36. Reeves KD and Hassanein K. Randomized prospective double-blind placebo-controlled study of dextrose prolotherapy for knee osteoarthritis with or without ACL laxity. *Alternative Therapies*. March 2000. 6(2):68-80.
37. Stoller D. *Magnetic Resonance Imaging in Orthopaedics and Sports Medicine*. Second Edition. Philadelphia, PA. Lippincott-Raven. 1997. p 330.
38. Hull ML, Berns GS, Verma H, and Patterson HA. Strain in the medial collateral ligament of the human knee under single and combined loads. *J Biomechanics*. 1996. 26(2):199-206.
39. Reider B. Medial collateral ligament injuries in athletes. *Sports Medicine*. 1996. 21(2):147-156.
40. *Ibid* ref 12: Ombregt L, Bisschop P, and ter Veer HJ. p 1103.
41. *Ibid* ref 12: Ombregt L, Bisschop P, and ter Veer HJ. p 1108.
42. Hauser R. *Prolotherapy: An Alternative to Knee Surgery*. Beulah Land Press. Oak Park, IL. 2004. p 103.
43. *Ibid* ref 12: Ombregt L, Bisschop P, and ter Veer HJ. p 1132.
44. Cyrlax JH. *Textbook of Orthopaedic Medicine*, Volume 1. *Diagnosis of Soft Tissue Lesions*, 8th edn. Balliere Tindall, London. 1982.
45. *Ibid* ref 12: Ombregt L, Bisschop P, and ter Veer HJ. p 1132.
46. Shalaby M and Almekinders LC. Patellar tendinitis: the significance of magnetic resonance imaging findings. *American Journal of Sports Medicine*. 1999. 27(3):345-349.
47. Stanitski CL. Correlation of Arthroscopic and Clinical Examinations With Magnetic Resonance Imaging Findings of Injured Knees in Children and Adolescents. *American J of Sports Medicine*. 1998. 26:2-6.
48. Burton M and Drezner J. Lower extremity overuse injuries in women. *Women's Health in Primary Care*. October 2006. p 15-32.
49. Fulkerson J and Hungerford D. *Disorders of the Patellofemoral Joint*, 2nd ed. Williams & Wilkins. Baltimore. 1990.
50. Dixit S, Burton M, and Mines B. Management of Patellofemoral Pain Syndrome. *American Family Physician*. January 2007. 75(2):194-202.
51. *Ibid*.